

Functional magnetic resonance imaging detects activation of the visual association cortex during laser acupuncture of the foot in humans

Christian M. Siedentopf^a, Stefan M. Golaszewski^{b,*}, Felix M. Mottaghy^c,
Christian C. Ruff^d, Stephan Felber^a, Andreas Schlager^e

^aDepartment of Radiology II, University Hospital of Innsbruck, Innsbruck, Austria

^bDepartment of Neurology, University Hospital of Graz, Auenbruggerplatz 22, 8036 Graz, Austria

^cDepartment of Nuclear Medicine (KME), Research Center Jülich, Jülich, Germany

^dCenter for Cognitive Science IIG, University of Freiburg, Freiburg, Germany

^eDepartment of Anaesthesiology and Critical Care Medicine, University Hospital of Innsbruck, Innsbruck, Austria

Received 21 January 2002; received in revised form 25 March 2002; accepted 11 April 2002

Abstract

The aim of this study was to investigate the effect of laser acupuncture on cerebral activation. Using functional magnetic imaging (fMRI) cortical activations during laser acupuncture at the left foot (Bladder 67) and dummy acupuncture, were compared employing a block design in ten healthy male volunteers. All experiments were done on a 1.5 Tesla magnetic resonance scanner equipped with a circular polarized head coil. During laser acupuncture, we found activation in the cuneus corresponding to Brodmann Area (BA) 18 and the medial occipital gyrus (BA 19) of the ipsilateral visual cortex. Placebo stimulation did not show any activation. We could demonstrate that laser acupuncture of a specific acupoint, empirically related to ophthalmic disorders, leads to activation of visual brain areas, whereas placebo acupuncture does not. These results indicate that fMRI has the potential to elucidate effects of acupuncture on brain activity. © 2002 Elsevier Science Ireland Ltd. All rights reserved.

Keywords: Laser acupuncture; Acupoint Bladder 67; Functional magnetic resonance imaging; Visual cortex

Acupuncture represents one of the oldest and still most frequently employed treatments worldwide. In the West, acupuncture has become generally known lately, however, its acceptance has increased rapidly. The National Institute of Health (USA) recommended acupuncture as an alternative therapy to the American medical professions which can essentially claim scientific validity and suggested that future clinical studies should compare acupuncture with conventional therapy in randomized studies. Acupuncture can be used to treat or support treatment of acute and chronic pain, postoperative and chemotherapy-induced nausea and vomiting, some forms of bronchial asthma, headache, migraine and drug abuse [13]. Several hypotheses exist to explain the therapeutic effects of acupuncture. For example, the analgesic effects of acupuncture are widely believed to be

mediated through descending inhibitory pathways localized to the brainstem [5,11,12,16]. Several structures like mesencephalon, hypothalamus, nucleus accumbens and the limbic system are known to be involved in this analgesic mechanism [5,6,19,21]. Recent functional brain imaging studies could demonstrate the effect of needle acupuncture and the influence of the activities of specific areas of the brain [1,2,6,7,20]. However, relatively few findings have been gained in the area of laser acupuncture. Since laser acupuncture is of considerable practical relevance, we investigated the effect of laser acupuncture on cerebral activation patterns in normal, healthy volunteers using functional magnetic resonance tomography (fMRI). For laser acupuncture, we selected the acupoint Bladder 67 (BL 67) which has been previously studied using needle acupuncture [1].

This study comprises ten healthy, right-handed, naive to acupuncture and medication-free male volunteers (age, 18–38 years; average age, 25.2 ± 5.5) without any history of neurological, psychiatric or internal disorders and no history of drug abuse. All subjects signed a written consent form

* Corresponding author. Tel.: +43-316-385-3136; fax: +43-316-385-6808.

E-mail address: stefan.golaszewski@uibk.ac.at (S.M. Golaszewski).

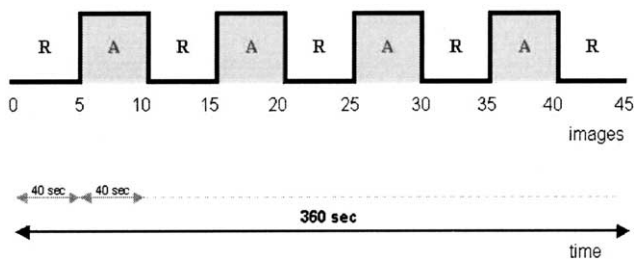


Fig. 1. Sequence design in the fMRI experiment.

and the study protocol was approved by the local ethics committee. For acupuncture, we selected the left acupoint BL 67 (ZhiYin) which is located at the lateral nail angle of the little toe. The acupoint BL 67 is traditionally used to treat a variety of eye disorders. BL 67 of the volunteers was identified with an acupoint detector (Silberbauer®-Austria). The acupuncture was performed with a low power diode laser (Minilaser 2010F®, Helbo-Medizintechnik, Gallspach, Austria) that operates with a continuous laser beam, 10 mW power output and a wave length of 670 nm.

The protocol consisted of two fMRI runs in each volunteer. Subjects were instructed to remain relaxed with their hands upon the abdomen, to keep their eyes closed and not to focus on any specific mental activity. The light within the magnet room was dimmed and during measurement there were no other sounds besides the scanner noise. The first fMRI run was a dummy stimulation (DS) with the acupuncture laser device at acupoint BL 67. During DS, the device was placed onto the skin targeting acupoint BL 67 prior to the start of the fMRI measurement to elicit the same tactile stimulus as during the laser stimulation (LS). Throughout the fMRI measurement, the device remained without moving exactly in the same position and the laser light was switched off. The second fMRI run was the LS of acupoint BL 67, completely identical to the DS, but now the laser light was alternately switched on and off. A direct activation of the visual system through the laser light can be excluded since the laser was situated on the foot outside the magnetic resonance (MR)-scanner behind a black screen and the head was situated in the head coil inside the MR-scanner.

In order to exclude conditioning and long-lasting effects of the LS, we scheduled the DS before the LS. Due to the well-established fact that blood oxygen level dependent-imaging detects haemodynamic changes, we performed the DS to show that our experimental setting did not induce any other activations beside those of laser acupuncture. Furthermore, we needed the DS to blind the subjects to exclude effects of anticipation. Due to the fact that the only difference between LS and DS was switching the light on/off, the volunteers could not distinguish DS from LS. The subjects were told that the dummy and LS would be presented in a random order.

We employed a block design with two conditions (on and off) with each block lasting 40 s in which five images

(TR = 8 s) were acquired (time series: RARARARAR; Fig. 1). For the LS, the light was only switched on during the on condition, in the dummy condition the light was switched off during the whole run. Prior to the time series, five dummy images were collected and excluded from data analysis. Foam padding and a special helmet fixed to the head coil were used to restrict head motions during all measurements (Fig. 2).

All experiments were performed on a 1.5 Tesla whole body scanner (Magnetom VISION, Siemens, Germany) with an echo-planar capable gradient system (rise time, 300 μ s; gradient strength, 25 mT/ms) and a circular polarized head coil (field of view = 250 mm). For fMRI, we employed T2* weighted single shot echo-planar sequences (scan repetition time (TR) = 0.96 ms, scan echo time (TE) = 66 ms, $\alpha = 90^\circ$, matrix = 128 \times 128, voxel dimension = 1.95 \times 1.95 \times 3.8 mm) [9,10,14,15]. We acquired 35 slices parallel to the bicommissural plane. Post-processing of fMRI data was done offline on a computer workstation using Matlab (Version 5.3) and SPM99 (SPM99, The Wellcome Department of Cognitive Neurology, University College London, UK) [18]. The 45 volume images were automatically realigned to the first image of the time series to correct for head movements between scans,

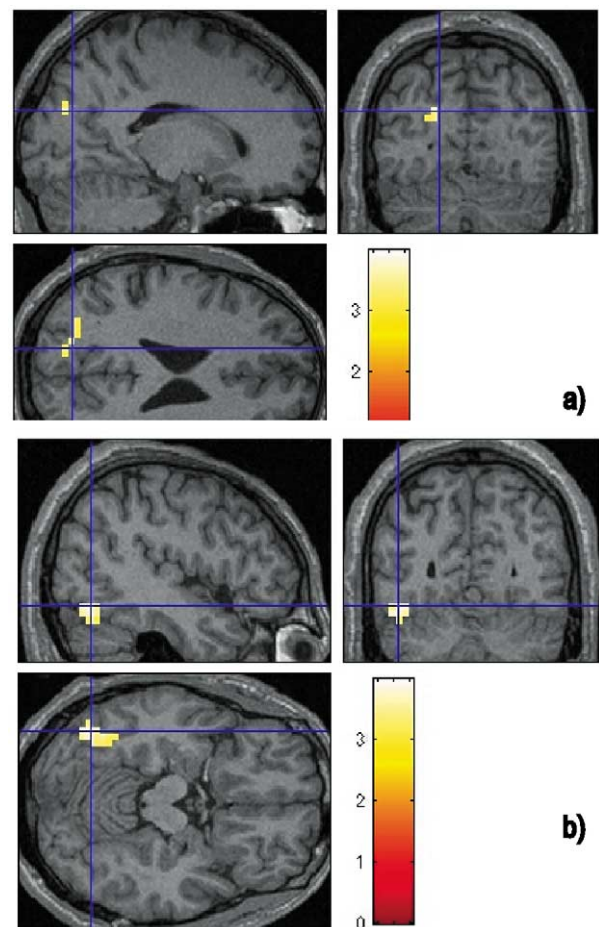


Fig. 2. Cerebral activation pattern induced by laser acupuncture.

normalized and transformed into the Talairach space [17]. Spatial and temporal smoothing were done with a Gaussian filter of $FWHM = 6 \times 6 \times 12$ mm. For the elimination of respiration and liquor pulsation related motion artefacts, high (cut-off: 0.001 Hz) and low (cut-off: 0.1 Hz) pass filtering was done. We defined a design matrix comprising contrasts testing for significant activation during DS and LS. A statistical parametric activation map was calculated for each subject on cluster level using a corrected P value of $P < 0.05$, corrected for multiple comparisons [3,4]. Anatomical location of the activated foci was assigned with the aid of the atlas of Talairach and Tournoux [17].

In the dummy condition, no significant activation was observed. The statistical analysis of the laser verum stimulation showed activations (Table 1) on the contralateral left hemisphere within the cuneus BA 18 cluster size 10, $P_{\text{corr}} < 0.049$) and the medial occipital gyrus (BA, 19 cluster size 28, $P_{\text{corr}} < 0.007$). On the contralateral right hemisphere, no activations were detected.

The results of this study are a further step to understand the underlying mechanisms of acupuncture. We found a similar activation pattern like Cho et al. with regard to the visual association cortex within BA 18 and 19 in the left hemisphere. No activation within corresponding areas of the right hemisphere could be detected. However, we could not line out brain activity within primary visual cortex BA 17 as Cho did [1] and our activations were not bilateral. The detected BA 18 and 19 are involved in higher order visual processing.

The dummy acupuncture at the same acupoint BL 67 did not show any brain activity. Therefore, the brain activation during the LS condition must originate from the effect of laser acupuncture. We suppose that our results are reliable since we were able to perform a ‘true’ dummy (placebo) acupuncture which is not possible with needle acupuncture studies [7]. After stimulation, subjects were asked about their sensations with regard to ‘prolonged channel sensation’ (PCS or *deqi*), a local mixture sensation including tingling, fullness and heaviness which is typical for needle acupuncture [16] and about any visual perception. Due to the fact that laser acupuncture did not elicit PCS in our subjects, we did not have to deal with the problem whether verum acupuncture was indistinguishable from DS.

We can exclude that the tactile stimulus has any influence on the cortical activation pattern of the brain because it does not correlate with the periodicity of the time series of our paradigms. This has been proven with the DS when the tactile stimulus was a constant afferent somatosensory input which showed no brain activity. Furthermore, the constant tactile stimulus is processed via the slow adapting low threshold mechanoreceptors (Merkel and Ruffini corpuscles) to the dorsal column of the myelon, the dorsal brainstem nuclei, via the lemniscus medialis to the contralateral thalamus and further primarily to the contralateral SI and bilateral SII (BA 3a,b, 1, 2, 5). Therefore, we conclude that the brain activity we found is not due to peripheral afferent input from the dermal mechanoreceptors because our brain activation map presents only ipsilateral activity within BA 18 and 19. Due to these findings, we assume that the Merkel and Ruffini corpuscles, which are augmented at acupoints [8], are not involved in the underlying mechanism of acupuncture.

Another important finding in our study is that, for the first time, we were able to demonstrate that laser acupuncture can induce brain response. This has already been proven for needle acupuncture. With regard to the fact that with laser acupuncture we elicited only ipsilateral brain activation within the brain cortex lacking any contralateral component, we suppose that acupuncture is not based upon afferent sensory information processing. Our results are in agreement with other studies [1,2,6,7,20] that show the involvement of a corresponding brain area for a specific acupoint.

Our results are promising for future functional brain imaging studies on the therapeutic effects of acupuncture. However, many questions still remain unanswered. For instance, it has to be elucidated how these transient changes in the fMRI signal that likely correspond to changes in regional brain activity lead to therapeutic effects on the target organ. A further question is how these results in healthy subjects can be generalized and applied to patients with disorders responsive to acupuncture.

This preliminary study gives evidence that laser acupuncture can activate a network of cortical and brainstem structures in the human brain and might lead to a modulation of this neuronal network. This could constitute the initiating steps by which acupuncture regulates multiple physiological

Table 1

Activation clusters detected for the contrasts of the images acquired during laser on and off conditions^a

Location			P value	Size (voxels)	MNI-coordinates ^b		
					X	Y	Z
<i>Laser on versus off</i>							
L	Medial occipital gyrus	(BA 19)	0.007	28	-44	-68	-8
L	Cuneus	(BA 18)	0.049	10	-20	-76	24

^a Statistical evaluation was done on a cluster-level inference with a P value of <0.05 , corrected for multiple comparisons across the whole brain. The same analysis of the DS shows no statistically significant activation cluster.

^b MNI = Montréal Neurological Institute.

systems and accomplishes a variety of empirically obvious therapeutic effects.

The work was supported by the Biomed2 Project Grant PL 950870 of the European Community.

- [1] Cho, Z.H., Chung, S.C., Jones, P.J., Park, J.B., Park, H.J., Lee, H.J., Wong, E.K. and Min, B.I., New findings of the correlation between acupoints and corresponding brain cortices using functional MRI, *Proc. Natl. Acad. Sci. USA*, 95 (1998) 2670–2673.
- [2] Cho, Z.H., Na, C.S., Wang, E.K., Lee, H.S. and Hong, I.K., Functional magnetic resonance imaging of the brain in the investigation of acupuncture, In G. Stux and R. Hammerschlag (Eds.), *Clinical Acupuncture; Scientific Basis*, Springer-Verlag, Berlin, 2001, pp. 83–95.
- [3] Friston, K.J., Worsley, K.J., Frackowiak, R.S.J., Mazziotta, J.C. and Evans, A.C., Assessing the significance of focal activations using their spatial extent, *Hum. Brain Mapp.*, 1 (1994) 214–220.
- [4] Friston, K.J., Holmes, A., Poline, J.B., Price, C.J. and Frith, C.D., Detecting Activations in PET and fMRI: levels of inference and power, *Neuroimage*, 1 (1995) 223–235.
- [5] Han, J.S. and Terenius, L., Neurochemical basis of acupuncture analgesia (Review), *Annu. Rev. Pharmacol. Toxicol.*, 22 (1982) 193–220.
- [6] Hsieh, J.C., Tu, C.H., Chen, F.P., Chen, M.C., Yeh, T.C., Cheng, H.C., Wu, Y.T., Liu, R.S. and Ho, L.T., Activation of the hypothalamus characterizes the acupuncture stimulation at the analgesic point in humans: a positron emission tomography study, *Neurosci. Lett.*, 307 (2001) 105–108.
- [7] Hui, K.K., Liu, J., Makris, N., Gollub, R.L., Chen, A.J., Moore, C.I., Kennedy, D.N., Rosen, B.R. and Kwong, K.K., Acupuncture modulates the limbic system and subcortical gray structures of the human brain: evidence from fMRI studies in normal subjects, *Hum. Brain Mapp.*, 9 (2000) 13–25.
- [8] Kellner, G., On a vascularized nerve-ending corpuscle of the Krause end-organ type, *Z. Mikrosk. Anat. Forsch.*, 75 (1966) 130–144.
- [9] Kwong, K.K., Functional magnetic resonance imaging with echo planar imaging, *Magn. Reson. Q.*, 11 (1995) 1–20.
- [10] Kwong, K.K., Belliveau, J.W., Chesler, D.A., Goldberg, I.E., Weisskoff, R.M., Poncelet, B.P., Kennedy, D.N., Hoppel, B.E., Cohen, M.S. and Turner, R., Dynamic magnetic resonance imaging of human brain activity during primary sensory stimulation, *Proc. Natl. Acad. Sci. USA*, 89 (1992) 5675–5679.
- [11] Liu, X. and Zhu, B., Relationship between electroacupuncture analgesia and descending pain inhibitory mechanism of nucleus raphe magnus, *Pain*, 24 (1986) 383–396.
- [12] Melzack, R., Folk medicine and the sensory modulation of pain, In P.D. Wall and R. Melzack (Eds.), *Textbook of Pain*, Churchill Livingstone, Edinburgh, 1989, pp. 897–905.
- [13] NIH Consensus Statement, 15(5) (1997 Nov 3–5) 1–34.
- [14] Ogawa, S., Lee, T.M. and Kay, A.R., Brain magnetic resonance imaging with contrast dependant on blood oxygenation, *Proc. Natl. Acad. Sci. USA*, 87 (1990) 9868–9872.
- [15] Ogawa, S., Tank, D.W. and Menon, R., Intrinsic signal changes accompanying sensory stimulation: functional brain mapping with magnetic resonance imaging, *Proc. Natl. Acad. Sci. USA*, 89 (1992) 5951–5955.
- [16] Pomeranz, B., Scientific basis of acupuncture, In G. Stux and B. Pomeranz (Eds.), *Basics of Acupuncture*, Springer-Verlag, Berlin, 1997.
- [17] Talairach, J. and Tournoux, P., *Co-Planar Stereotaxic Atlas of the Human Brain*, Thieme Medical Publishers, Georg Thieme Verlag, Stuttgart, 1988.
- [18] The Wellcome Department of Cognitive Neurology, University College London, UK, <http://www.fil.ion.ucl.ac.uk>.
- [19] Wang, Q.A., Mao, L. and Han, J., The arcuate nucleus of hypothalamus mediates low but not high frequency electroacupuncture analgesia in rats, *Brain Res.*, 513 (1990) 60–66.
- [20] Wu, M.T., Hsieh, J.C., Xiong, J., Yang, C.F., Pan, H.B., Chen, Y.C., Tsai, G., Rosen, B.R. and Kwong, K.K., Central nervous pathway for acupuncture stimulation: localization of processing with functional MR imaging of the brain—preliminary experience, *Radiology*, 212 (1999) 133–141.
- [21] Yu, L.C. and Han, J.S., Involvement of arcuate nucleus of hypothalamus in the descending pathway from nucleus accumbens to periaqueductal grey subserving an antinociceptive effect, *Int. J. Neurosci.*, 48 (1989) 71–78.